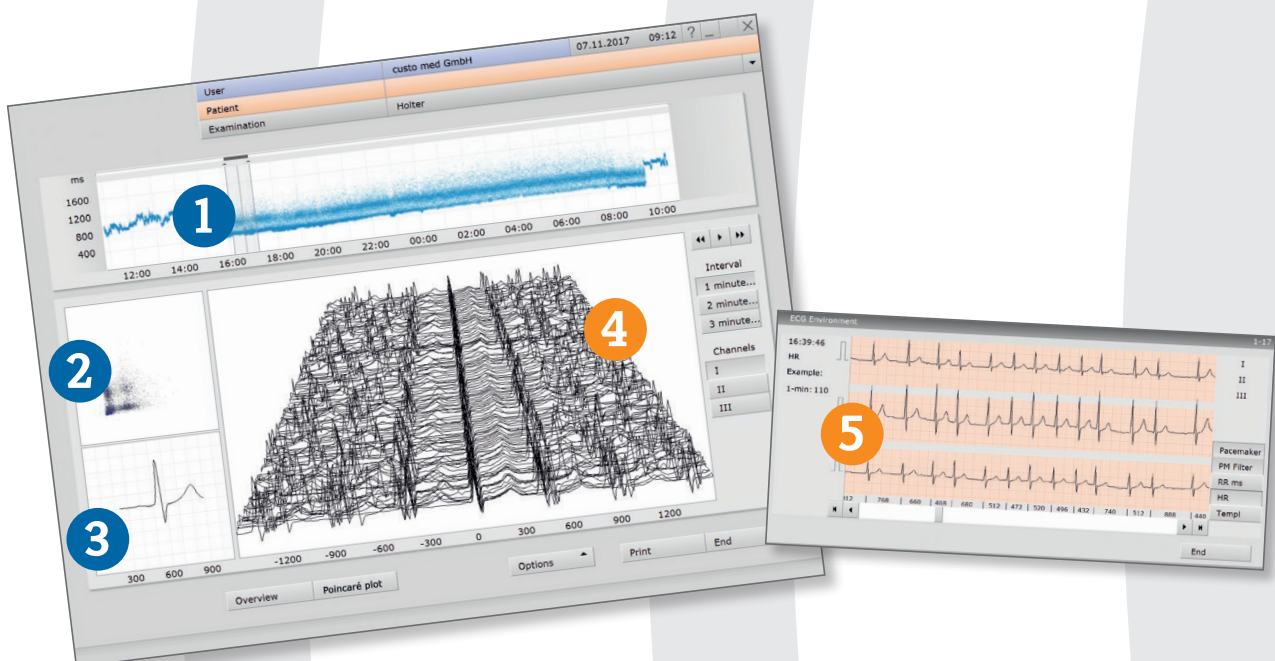


custo AF

Detect Atrial Fibrillation

easy - fast - reliable

The way towards unambiguous AF diagnostics is made in five steps. An initial suspicion of atrial fibrillation can thus be confirmed or rejected easily, fast and reliably.



Identification

- 1 In the RR trend, high-frequency areas which may deviate from sinus rhythm can be well identified. They can be selected with a mouse-click.
- 2 The Poincaré plot shows if there is sinus rhythm ("cigar shape"), arrhythmia (e. g. VES, then "butterfly shape") or atrial fibrillation (diffuse "point cloud").
- 3 The summary complex shows whether or not a P wave exists.

Verification

- 4 In the mountain view ECG, for example, the beginning of a paroxysmal fibrillation episode can be detected easily and quickly. With a double click on the ECG curve the original ECG is called up.
- 5 The original ECG allows to make a definite evaluation. **As of now, unclear and uncertain diagnoses with respect to atrial fibrillation belong to the past.**